

CASE REPORT

Open Access



Removing and reimplanting deep brain stimulation therapy devices in resistant OCD (when the patient does not respond): case report

Eva Real^{1,2}, Gerard Plans^{3*}, Pino Alonso^{1,2,4}, Marco A. Aparicio³, Cinto Segalàs^{1,2}, Narcís Cardoner^{1,2,5}, Carles Soriano-Mas^{1,2}, Clara López-Solà^{1,2} and José M. Menchón^{1,2,4}

Abstract

Background: Deep brain stimulation (DBS) is emerging as a promising tool in the treatment of refractory obsessive-compulsive disorder (OCD) but the search for the best target still continues. This issue is especially relevant when particularly resistant profiles are observed in some patients, which have been ascribed to individual responses to DBS according to differential patterns of connectivity. As patients have been implanted, new dilemmas have emerged, such as what to do when the patient does not respond to surgery.

Case presentation: Here we describe a 22-year-old male with extremely severe OCD who did not respond to treatment with DBS in the nucleus accumbens, but who did respond after explanting and reimplanting leads targeting the ventral capsule-ventral striatum region. Information regarding the position of the electrodes for both surgeries is provided and possible brain structures affected during stimulation are reviewed. To our knowledge this case is the first in the literature reporting the removal and reimplantation of DBS leads for therapeutic benefits in a patient affected by a mental disorder.

Conclusion: The capability for explantation and reimplantation of leads should be considered as part of the DBS therapy reversibility profile in resistant mental disorders, as it allows application in cases of non-response to the first surgery.

Keywords: Deep brain stimulation, Obsessive-compulsive disorder, Device removal, Treatment outcome

Background

The scientific and ethical issues in the application of deep brain stimulation (DBS) in resistant psychiatric disorders continue to be debated (reviewed in [1]). In the case of obsessive-compulsive disorder (OCD), ablative psychosurgery has been the last-resort treatment for refractory patients in recent decades [2]. However, the therapeutic benefits reported for this approach are clouded by its potential adverse effects, especially impairment in frontal lobe functioning [3, 4]. In this context, DBS has emerged

as an attractive alternative and has progressively replaced ablative surgery in resistant OCD and depression.

As patients have been implanted, new dilemmas have emerged, such as what to do when the patient does not respond to surgery. Device removal is often required for clinical cure when leads or generator pocket infection occurs. This procedure (and device reimplantation) has been previously reported for movement disorders [5–7], but not for therapeutic purposes in mental disorders. The patient described here is a treatment-refractory OCD participant on a DBS treatment program run by at the OCD Clinical and Research Unit of Bellvitge University Hospital. He was explanted and reimplanted (in a different location and using different leads) due to very low therapeutic benefit after the first surgery.

* Correspondence: gplans@bellvitgehospital.cat

³Department of Neurosurgery, Bellvitge University Hospital, C/ Feixa Llarga s/n, 08907 Hospitalet del Llobregat, Barcelona, Spain

Full list of author information is available at the end of the article

Case presentation

Clinical history

A 22-year-old male with extremely severe OCD underwent DBS and pulse generator implantation in September 2009. The patient and his family reported severe obsessive-compulsive symptomatology since childhood: at 11 he began to manifest magical thoughts and compulsions involving “just-right” symptoms, symmetry and perfectionism, slowness in writing, the need to hoard and to touch objects, and repeating and arranging rituals. The disease course had been progressively debilitating, with highly compulsive time wasting behavior that led to the abandonment of education and successive hospital admissions from the age of 13. After trying a wide variety of treatments the patient was enrolled on the DBS program. For reasons of space, some features of the case (as well as treatment resistance profile) are summarized in the Table 1.

First DBS surgery

Surgical procedure was performed according to Bellvitge Hospital DBS protocol for resistant OCD (L.D. B-29406-2012). The study protocol was approved by the ethics committee of Bellvitge University Hospital (CEIC Ciutat Sanitària i Universitària de Bellvitge).

Two quadripolar DBS electrodes (Model 3389 DBS lead; Medtronic, MN, USA) were bilaterally implanted in the nucleus accumbens (NAcc) region with the aid of a Leksell stereotactic frame (Elekta, Sweden). NAcc was one of the targets reported to be effective in the treatment of OCD with DBS [8, 9] and 3389 electrode was the one available in our setting at that moment. The target was referenced to the anterior commissure (AC) as described in previous studies [9]. The stereotactic brain surgery software BrainLab iPlan Stereotaxy 1.1 (Brain Lab, Germany) was used for target selection and trajectory planning. A postoperative stereotactic cranial CT scan was co-registered with the preoperative MRI to verify the final position of the electrodes within the first 24 hours. The position of each contact was referenced to the AC and coordinates were transferred to an anatomic atlas [10] to identify anatomic structure influenced during stimulation. The final position of the active contacts with respect to AC is shown in the Table 1.

Even though parameter testing and adjustment were the same as in other DBS implanted patients, no significant clinical improvements were achieved with the first surgery (Y-BOCS reduction from 38 to 35, less

Table 1 Patient characteristics and stimulation settings

Sex	Male			
Age at OCD Onset	11			
Age at surgery	19			
Worst YBOCS ever	38			
Worst HDRS ever	12			
Pharmacological resistance profile ¹	Fluoxetine 60 mg/d Fluvoxamine 300 mg/d Sertraline 200 mg/d Escitalopram 20 mg/d Clomipramine 300 mg/d		Venlafaxine 150 mg/d Phenelzine 60 mg/d Pimozide 2 mg/d Risperidone 3 mg/d Amisulpride 200 mg/d Aripiprazole 15 mg/d	
Treatment ²	1st Surgery CLM 262.5 mg/d + ESCIT 20 mg/d + RIS 1.5 mg/d + AGOM 25 mg/d		2nd Surgery CLM 265.5 mg/d + ESCIT 40 mg/d + RIS 1.5 mg/d	
Stimulation settings	0 + 1-, 210 μ s, 135 Hz, 4 V	4 + 5-, 210 μ s, 135 Hz, 4 V	0-1+, 270 μ s, 60 Hz, 3 V	5-6+, 270 μ s, 60 Hz, 3 V
Best YBOCS reached		35		26
Best HDRS reached		12		7
Best GAF reached		30		65
Position of the center of the stimulation*	Left (0–1)	Right (4–5)	Left (0–1)	Right (5–6)
x	5,29	10,54	9,02	8,57
y	5,47	3,54	-3,12	-4,46
z	-4,26	-0,85	2,87	-1,32

¹Pharmacological resistance profile refers to all the different pharmacological trials conducted during the whole follow-up (since the patient was first treated at 11 years old until he performed the first surgery). Doses of these drugs were maintained for at least 12 weeks, to complete the trials

²Treatment refers to the precise combination of drugs that the patient was taking when the best Y-BOCS and HDRS scores were achieved

*Distance from the anterior commissure (AC)

Abbreviations: OCD obsessive-compulsive disorder, Y-BOCS Yale-Brown Obsessive Compulsive Scale, HDRS Hamilton Depression Rating Scale, GAF Global Assessment Functioning scale, CLM clomipramine, ESCIT escitalopram, RIS risperidone, AGOM agomelatine, x lateral, y anteroposterior, z axial

than 10 % of basal YBOCS). The patient's quality of life remained very poor, and he needed further hospital admissions after DBS surgery. After a full explanation and with the consent of the patient and his family, the DBS electrodes were removed in March 2011. In April 2011 the patient underwent surgery for the second time. A baseline-assessment between the two implantations was done and clinical and psychometric measurements were performed (i.e.: Y-BOCS ratings dropped to the first intervention's previous levels).

Second DBS surgery

For the second surgical procedure we decided to use the ventral capsule/ventral striatum (VC/VS) target as it was reported to have the strongest evidence for therapeutic benefits at that moment [11]. The final theoretical target was calculated to be at the posterior border of the AC at the intercommissural level and 5 mm lateral to midline. The final trajectory was planned to cover the whole length of the anterior limb of the internal capsule (ALIC). For this purpose a Model 3391 DBS lead was used (the aim was to increase the setting options of the electric field, mainly in size, seeking the highest potential for clinical benefit in this especially resistant patient). The deepest active contacts on both sides (contact 0 on the left and contact 5 on the right) were located in the postero-ventral part of the ALIC (see Fig. 1). The stimulation protocol was conducted exactly the same way after both surgeries. So, any parameters combination tested in the 2nd surgery (including low-frequency paradigms) were also tested after the first implant, with null results.

After 16 weeks, compulsive behavior began to improve: YBOCS score fell from 35 to 26, a 32 % improvement compared with baseline (symptom severity in obsessions and compulsions decreased in parallel). A Dimensional Yale-Brown Obsessive-Compulsive Scale (DY-BOCS) was also scored after second surgery, showing that clinical improvement occurred mostly in the Aggressive-Checking dimension (Basal Severity Score: 15 vs Postsurgery Severity Score: 9, 40 % reduction) and secondly in the Symmetry-Ordering dimension (Basal Severity Score: 15 vs Postsurgery Severity Score: 10, 33 % reduction). The patient reports improved quality of life and a stabilization of daily life routines (in Table 1). Since hospital discharge (in June 2011) the patient remains stabilized with fluctuating moderate symptomatology (YBOCS 22 in April 2012, a 42 % improvement), but he has not needed further hospital admission.

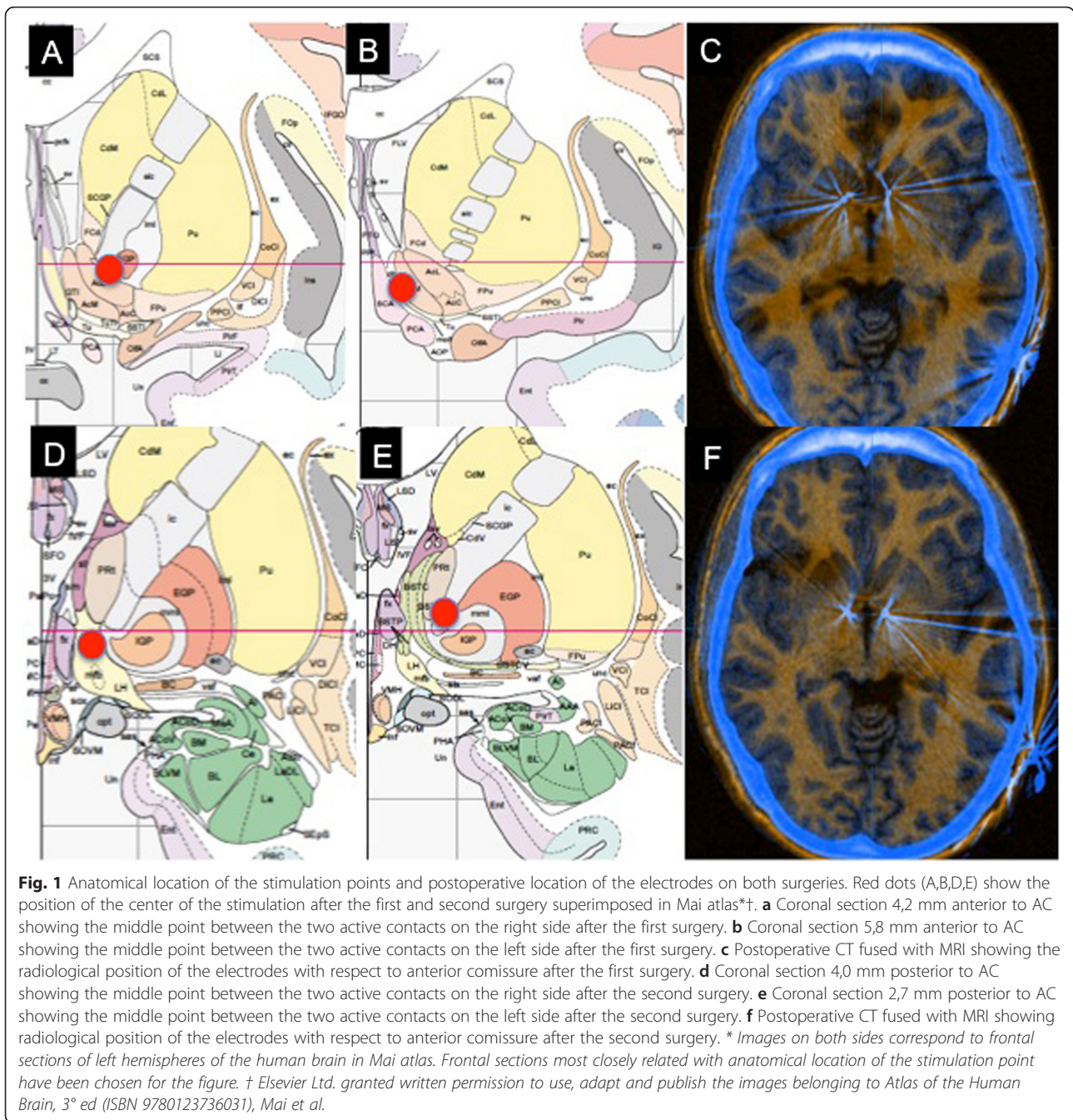
Discussion

Although there is broad consensus on the neuropathological correlates of OCD, the search for the "OCD target" for DBS is still ongoing. Various targets have been chosen

with the aim of modulating activity within the cortico-striato-thalamo-cortical circuit (CSTC) at one of its critical nodes. Some of these regions are the ALIC [12], the nucleus accumbens [13], the ventral caudate nucleus [14], the VS/VC [11], the inferior thalamic peduncle (ITP) [15] and the subthalamic nucleus [16], in which differing therapeutic benefits have been achieved. Clinical outcome for all studies yields a mean Y-BOCS reduction that ranges from 45.1 to 47.7 % and a global percentage of responders of 60 % [17, 18]. Previous evidence supported that reductions in OCD severity were greater in patients receiving NAcc and VC/VS stimulation (52-54 %) than in patients receiving STN stimulation (41 %) (reviewed in [17]). However, in a recently published meta-analysis comparing the response to DBS in all available OCD patients worldwide, no significant differences were detected between targets in terms of the percentage of reduction in Y-BOCS scores or in percentage of responders when striatal areas stimulation were compared to STN stimulation [17]. These results must be taken with caution, as studies are also heterogeneous in terms of electrode design and stimulation parameters (and patients are also clinically heterogeneous).

Our patient did not respond satisfactorily to the first surgery, although the neuroanatomical target used was similar to that used in other patients enrolled in our DBS program who did respond. We decided to use a double strategy for the second surgical procedure. First, we implanted the lead in a more posterior location. Targeting a more posterior region of the VS/VC has been associated with a greater YBOCS reduction [11]. The VS/VC has been reported to be a node of different CSTC circuits related with OCD symptoms. Neuromodulation of these circuits seem to be more effective with a more posterior location of the DBS electrodes since these circuits become more compact as they run posteriorly to the thalamus through the inferior thalamic peduncle (ITP) [11]. Indeed, in our patient, stimulation seems to be centred on the anatomical region of the ITP target described by Jimenez [15].

In the second intervention we also used a larger electrode (Model 3391). This lead was designed to cover the length of the ALIC (active contact length of 3 mm). It seems plausible that, if this lead stimulates a wider range of neuroanatomical areas, the combination of parameters including the optimum target for this patient is more likely to be found with the second implant. The final position of the active contacts is in close relation with certain brain structures believed to be involved in pathophysiological aspects of OCD (Fig. 1). The bed nucleus of the stria terminalis (left side) has been related to anxiety expression in some experimental models [19], and the medial forebrain bundle (the deepest active contact on the right side) is known to be a key structure in the brain's



reward circuitry with a potential involvement in compulsive behavior [20]. Although it is speculative, this could lead us to hypothesize that different subgroups of OCD (according to phenotypic differences) could respond better depending on the target stimulated. Unfortunately, data available in literature does not allow drawing reliable conclusions on this issue due to several reasons: the number of patients included in OCD DBS studies are insufficient to allow comparisons between targets, OCD DBS studies differ in electrode design and stimulation protocols used (which also hampers the

comparison between clinical issues and targets), and current magnetic resonance imaging does not have enough resolution to find differences between NAcc and VC/VS (which are very close).

The therapeutic response after the second surgery was moderate despite optimal anatomic placement, and multiple stimulation parameter settings were performed for several months (monopolar, bipolar, stimulation of multiple contacts). This particularly resistant profile observed in some patients has been ascribed to an individual response to DBS, according to differential clinical features

and patterns of connectivity (reviewed in Lipsman) [21]. It has been reported that ‘just-right’ experiences or the need for symmetry exhibited by our patient may be less likely to respond to DBS [22, 23]. Moreover, early onset OCD has been associated to a worse response to DBS when all targets are considered as a whole [17]. Regarding the existence of differential patterns of connectivity, the use of neuroimaging techniques such as diffusion tensor imaging (DTI)-based tractography has been proposed to identify the precise trajectory of tracts at a single subject level in depression [24].

The patient described became a responder after reimplantation of DBS electrodes in the VS/VC target in a more posterior location. The stimulation of different brain areas after an unsuccessful implantation has been previously described in Tourette syndrome patients with severe comorbid OCD (adding bilateral ALIC/NAcc region DBS leads to the existing Vo/CM-Pf stimulation or through de novo ALIC/NAcc DBS plus Vo/CM-Pf region stimulation) [25]. However, the explantation and reimplantation of DBS devices has not been previously reported in the literature for therapeutical benefits in resistant OCD.

The experience of our case brings us back to the debate on which is the best target for OCD, as the stimulation of both targets (NAcc and VC/VS) have been reported to be effective in resistant patients. They are very close and one could think that the stimulation of one would influence the activity of the other, as they are critical nodes within the CSTC circuit. Evidence in the literature does not allow us to know why our patient did not benefit from the first implantation in NAcc (although he did from the second implantation, in VC/VS) nor why he responded while receiving low frequency DBS. Although it is speculative, it cannot be discarded that some targets might be more sensitive to electric stimulation than others (due to still unknown mechanisms). It would be similar to the fact that some patients respond to certain selective serotonin reuptake inhibitors (SSRIs), but not to others (when all drugs belong to the same family and theoretically share the same mechanism of action). The target selection is further complicated, as it has been demonstrated with neuroimaging data that even within the same NAcc, the actual stimulation coordinates vary substantially between patients, which significantly influence on clinical outcomes [26]. So, depending on the specific stimulation site, different fiber bundles and therefore different sets of structures may be affected [11]. From an electrophysiological point of view, stimulation both hyperpolarize and depolarize neurons and activation of axons may have distal effects, including overall excitation or inhibition through stimulation of inhibitory neurons. This indicates that DBS may evoke multiple effects (reviewed

in [27]). The benefits of low-frequency DBS has been reported in animal models of OCD. The 8-OHDPAT-induced decreased alternation model might serve to model two specific aspects of OCD, namely perseveration and indecision (reviewed in [17]). In this rat model, low- but not high-frequency stimulation (HFS) of the thalamic nucleus is effective in reducing 8-OHDPAT-induced perseveration [28] whereas HFS of the STN has shown anti-OCD effects in humans [29]. Future research will help to integrate findings coming from different research approaches.

Some weaknesses might be considered: 1) potential effects of other concurrent interventions performed when the patient responded (besides the explantation and the stimulation of a new target) cannot be discarded. This interventions include slight changes in medication, change in type of electrodes, changes in stimulation parameters and possibly a change in volume of tissue activated (VTA) post surgery 1 vs post surgery 2. Unfortunately, we are unable to ensure in which extent these interventions were involved in the clinical benefit. We think that VTA in second surgery represented a smaller contribution in clinical improvement. Although we cannot estimate the VTA directly, we have calculated charge densities in first and second surgeries (this parameter is proportional to VTA), resulting that it was about half in the second surgery, compared to the first surgery (data to perform the calculation are available at the Table 1). On the other hand, although some reports suggest that DBS may allow previously ineffective pharmacological treatments to become effective [30], it is difficult for the authors to assume that the rise of the dose of an SSRI drug may be responsible for the improvement of a patient who did not respond to very potent drugs as phenelzine or clomipramine at full doses; 2) On the other hand, a morphing of the atlas to the patient’s own landmarks was not performed to determine anatomic localization of the target. However, the authors believe that this did not affect significantly to the accuracy of the final positioning of leads.

Conclusions

Our report emphasizes the reversibility profile of DBS, and helps to dissociate it from the historical negative connotations of psychosurgery. Following up a patient with persisting disabling symptoms and very poor quality of life implies an ethical and clinical dilemma, especially when the alternative of a second surgery is not exempt from risks. Although the experience of a case cannot be extrapolated to another, the authors believe that a second surgery could be considered after 18 months of non-response to the first surgery in OCD resistant patients (when all programming possibilities

have been exhausted). The capability for explantation and reimplantation of DBS leads should be considered as part of DBS reversibility profile in resistant mental disorders, as it allows application in cases of non-response to the first surgery.

Consent

Written informed consent was obtained from the patient for publication of this Case report and any accompanying images. A copy of the written consent is available for review by the Editor of this journal.

Competing interests

The authors declare that they have no competing interests.

Authors' contributions

PA, CS, CL-S, ER, participated in the clinical follow-up of the patient and in the interpretation of data. GP, MA, performed both surgical procedures and participated in the clinical follow-up and in the interpretation of data. ER, GP, NC, CS-M, JM, participated in the interpretation of data and writing of the manuscript. All the authors received, reviewed and approved the final version of the paper to be published.

Acknowledgements

This study was supported in part by Instituto de Salud Carlos III (ISCIII) (CP10/00604, PI10/01753, PI11/210, PI13/00918, PI13/01958, PI14/00413), FEDER funds/ European Regional Development Fund (ERDF) -a way to build Europe-, CIBERSAM and AGAUR (2014 SGR 1672). ER was supported by a Juan Rodés contract (JR14/00038) and CS-M was supported by a Miguel Servet contract (CP10/00604) from the ISCIII. CL-S was supported by the Ministerio de Educación, Cultura y Deporte de España (FPU12/01636).

These funding bodies had no specific role in the preparation, review, or approval of the manuscript.

The authors thank the study participant of this report and his family, and thank Michael Maudsley for help with the English.

Author details

¹Psychiatry Department, Bellvitge University Hospital, Bellvitge Biomedical Research Institute (IDIBELL), C/ Feixa Llarga s/n, 08907 Hospitalet del Llobregat, Barcelona, Spain. ²Carlos III Health Institute, Centro de Investigación Biomédica en Red de Salud Mental (CIBERSAM), Madrid, Spain. ³Department of Neurosurgery, Bellvitge University Hospital, C/ Feixa Llarga s/n, 08907 Hospitalet del Llobregat, Barcelona, Spain. ⁴Department of Clinical Sciences, School of Medicine, University of Barcelona, Barcelona, Spain. ⁵Mental Health Department, Corporació Sanitària Parc Taulí, Sabadell, Spain.

Received: 3 June 2015 Accepted: 1 February 2016

Published online: 06 February 2016

References

- Rabins P, Appleby BS, Brandt J, DeLong MR, Dunn LB, Gabriels L, et al. Scientific and ethical issues related to deep brain stimulation for disorders of mood, behavior, and thought. *Arch Gen Psychiatry*. 2009;66:931–7.
- Greenberg BD, Rezaei AR. Mechanisms and the current state of deep brain stimulation in neuropsychiatry. *CNS Spectr*. 2003;8:522–6.
- Mindus P, Rasmussen SA, Lindquist C. Neurosurgical treatment for refractory obsessive-compulsive disorder: implications for understanding frontal lobe function. *J Neuropsychiatry Clin Neurosci*. 1994;6:467–77.
- Ruck C, Andreevitch S, Flyckt K, Edman G, Nyman H, Meyerson BA, et al. Capsulotomy for refractory anxiety disorders: long-term follow-up of 26 patients. *Am J Psychiatry*. 2003;160:513–21.
- Gorgulho A, Juillard C, Uslan DZ, Tajik K, Aurasteh P, Behnke E, et al. Infection following deep brain stimulator implantation performed in the conventional versus magnetic resonance imaging-equipped operating room. *J Neurosurg*. 2009;110:239–46.
- Ramirez-Zamora A, Levine D, Sommer DB, Dalfino J, Novak P, Pilitsis JG. Intraparenchymal cyst development after deep brain stimulator placement. *Stereotact Funct Neurosurg*. 2013;91:338–41.
- Tolleson C, Stroh J, Ehrenfeld J, Neimat J, Konrad P, Phibbs F. The factors involved in deep brain stimulation infection: a large case series. *Stereotact Funct Neurosurg*. 2014;92:227–33.
- Kuhn J, Lenartz D, Mai JK, Huff W, Lee SH, Koulousakis A, et al. Deep brain stimulation of the nucleus accumbens and the internal capsule in therapeutically refractory Tourette-syndrome. *J Neurol*. 2007;254:963–5.
- Sturm V, Lenartz D, Koulousakis A, Treuer H, Herholz K, Klein JC, et al. The nucleus accumbens: a target for deep brain stimulation in obsessive-compulsive- and anxiety-disorders. *J Chem Neuroanat*. 2003;26:293–9.
- Mai JK, Paxinos G, and Voss T, Atlas of the Human Brain. 3rd edition: Academic Press ed. 2008: Elsevier Inc.
- Greenberg BD, Gabriels LA, Malone Jr DA, Rezaei AR, Friehs GM, Okun MS, et al. Deep brain stimulation of the ventral internal capsule/ventral striatum for obsessive-compulsive disorder: worldwide experience. *Mol Psychiatry*. 2010;15:64–79.
- Nuttin B, Cosyns P, Demeulemeester H, Gybels J, Meyerson B. Electrical stimulation in anterior limbs of internal capsules in patients with obsessive-compulsive disorder. *Lancet*. 1999;354:1526.
- Huff W, Lenartz D, Schormann M, Lee SH, Kuhn J, Koulousakis A, et al. Unilateral deep brain stimulation of the nucleus accumbens in patients with treatment-resistant obsessive-compulsive disorder: Outcomes after one year. *Clin Neurol Neurosurg*. 2010;112:137–43.
- Aouizerate B, Cuny E, Martin-Guehl C, Guehl D, Amieva H, Benazzou A, et al. Deep brain stimulation of the ventral caudate nucleus in the treatment of obsessive-compulsive disorder and major depression. Case report. *J Neurosurg*. 2004;101:682–6.
- Jimenez F, Nicolini H, Lozano AM, Piedimonte F, Salin R, Velasco F. Electrical Stimulation of the Inferior Thalamic Peduncle in the Treatment of Major Depression and Obsessive Compulsive Disorders. *World Neurosurg*. 2013;80(3–4):17–25.
- Mallet L, Polosan M, Jaafari N, Baup N, Welter ML, Fontaine D, et al. Subthalamic nucleus stimulation in severe obsessive-compulsive disorder. *N Engl J Med*. 2008;359:2121–34.
- Alonso P, Cuadras D, Gabriels L, Denys D, Goodman W, Greenberg BD, et al. Deep brain stimulation for obsessive-compulsive disorder: a meta-analysis of treatment outcome and predictors of response. *PLoS One*. 2015;10, e0133591.
- van Westen M, Rietveld E, Figeo M, Denys D. Clinical outcome and mechanisms of deep brain stimulation for obsessive-compulsive disorder. *Curr Behav Neurosci Rep*. 2015;2:41–8.
- Duvarci S, Bauer EP, Pare D. The bed nucleus of the stria terminalis mediates inter-individual variations in anxiety and fear. *J Neurosci*. 2009;29:10357–61.
- Coenen VA, Panksepp J, Hurwitz TA, Urbach H, Madler B. Human Medial Forebrain Bundle (MFB) and Anterior Thalamic Radiation (ATR): Imaging of Two Major Subcortical Pathways and the Dynamic Balance of Opposite Affects in Understanding Depression. *J Neuropsychiatry Clin Neurosci*. 2012;24:223–36.
- Lipsman N, Neimat JS, Lozano AM. Deep brain stimulation for treatment-refractory obsessive-compulsive disorder: the search for a valid target. *Neurosurgery*. 2007;61:1–11. discussion 11–3.
- Denys D, Mantione M, Figeo M, van den Munckhof P, Koerselman F, Westenberg H, et al. Deep brain stimulation of the nucleus accumbens for treatment-refractory obsessive-compulsive disorder. *Arch Gen Psychiatry*. 2010;67:1061–8.
- Greenberg BD, Malone DA, Friehs GM, Rezaei AR, Kubu CS, Malloy PF, et al. Three-year outcomes in deep brain stimulation for highly resistant obsessive-compulsive disorder. *Neuropsychopharmacology*. 2006;31:2384–93.
- Gutman DA, Holtzheimer PE, Behrens TE, Johansen-Berg H, Mayberg HS. A tractography analysis of two deep brain stimulation white matter targets for depression. *Biol Psychiatry*. 2009;65:276–82.
- Servello D, Sassi M, Brambilla A, Porta M, Haq I, Foote KD, et al. De novo and rescue DBS leads for refractory Tourette syndrome patients with severe comorbid OCD: a multiple case report. *J Neurol*. 2009;256:1533–9.
- van den Munckhof P, Bosch DA, Mantione MH, Figeo M, Denys DA, Schuurman PR. Active stimulation site of nucleus accumbens deep brain stimulation in obsessive-compulsive disorder is localized in the ventral internal capsule. *Acta Neurochir Suppl*. 2013;117:53–9.
- Bourne SK, Eckhardt CA, Sheth SA, Eskandar EN. Mechanisms of deep brain stimulation for obsessive compulsive disorder: effects upon cells and circuits. *Front Integr Neurosci*. 2012;6:29.
- Andrade P, Fernandez-Guasti A, Carrillo-Ruiz JD, Ulloa RE, Ramirez Y, Reyes R, et al. Effects of bilateral lesions in thalamic reticular nucleus and orbitofrontal cortex in a T-maze perseverative model produced by 8-OH-DPAT in rats. *Behav Brain Res*. 2009;203:108–12.

29. Jimenez-Ponce F, Velasco-Campos F, Castro-Farfan G, Nicolini H, Velasco AL, Salin-Pascual R, et al. Preliminary study in patients with obsessive-compulsive disorder treated with electrical stimulation in the inferior thalamic peduncle. *Neurosurgery*. 2009;65:203–9. discussion 209.
30. Aouizerate B, Cuny E, Rotge JY, Martin-Guehl C, Doumy O, Benazzouz A, et al. Is deep brain stimulation able to make antidepressants effective in resistant obsessive-compulsive disorder? *Biol Psychiatry*. 2012;71:e43–4.

Submit your next manuscript to BioMed Central
and we will help you at every step:

- We accept pre-submission inquiries
- Our selector tool helps you to find the most relevant journal
- We provide round the clock customer support
- Convenient online submission
- Thorough peer review
- Inclusion in PubMed and all major indexing services
- Maximum visibility for your research

Submit your manuscript at
www.biomedcentral.com/submit

